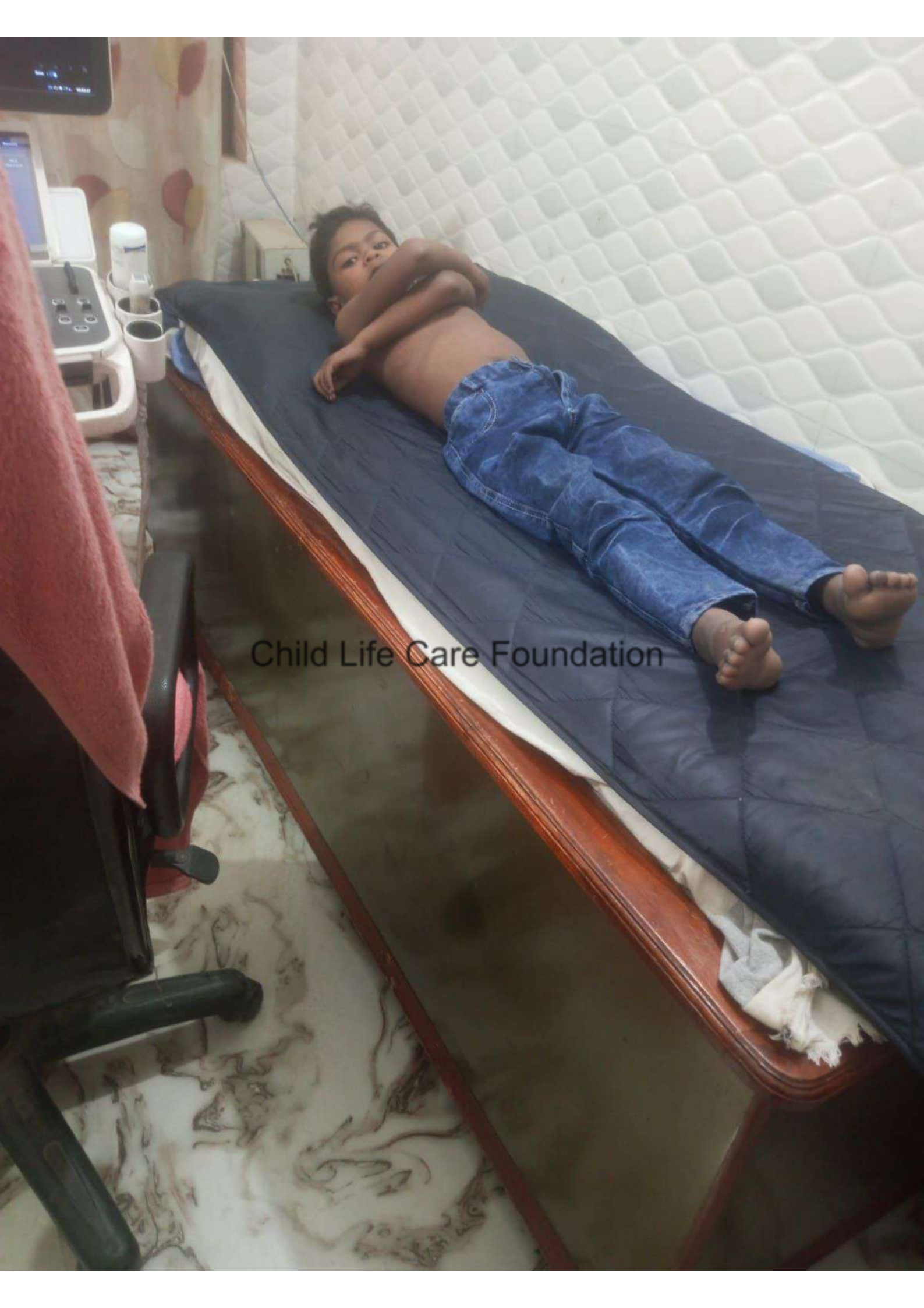



Child Life Care Foundation

**Measurements**

Aorta	Normal Values (21-22 mm/m <sup>2</sup> )
LV es <u>42</u>	(16-19 mm/m <sup>2</sup> )
IVS ed	(06-10 mm)
RV ed	(4-14mm/m <sup>2</sup> )
EF <u>60%</u>	(62-80%)
IVS Motion	Normal/Plat/Paradoxical
IAS	

LA es	Normal Values (21-22 mm/m <sup>2</sup> )
LV ed <u>52</u>	(19-32 mm/m <sup>2</sup> )
PW(LV)ed	(07-11mm)
RV Anterior Wall	(Upto 5mm)

**CHAMBERS**

LV	Normal/ <u>Enlarged</u> /Clear/Thrombus/Hypertrophy
LA	Contraction Normal/Reduced
RA	Normal/ <u>Enlarged</u> /Clear/Thrombus
RV	Normal/ <u>Enlarged</u> /Clear/Thrombus

*Agar*  
*Chromosomes*  
*29/12/24*

**PERICARDIUM**

Normal/Thickened/Calcification/Effusion.

**Child Life Care Foundation**

**REMARKS**

*segmental analysis*  
*intact IAS*

*s/A VSD (L → R, 14 ~ 45 mm)*  
*RCC prolapse*     *mod. AL*  
*[flow reversal in aorta only +]*

**TEE**

*LA/LV hugely dilated*     *mild eccentric*  
*LVID d/s ↓ 52/42*     *LVEDV ↑*

**DIAGNOSIS**

*~~LVEDV 50-55%~~ (mild LV dysfunction) NBV ↓*

**Final impression**

*① Atrial / No CoA / PDA*  
*No PPH/ob/VV*     *mild RL & PL*

*Large s/A VSD / RCC prolapse (Mod. AL)*  
*LVEDV ↑*

Resident

Consultant

*Consultant*  
*1/10*

*for VSD closure.*



# ECHOCARDIOGRAPHY REPORT

106

DEPARTMENT OF CARDIOLOGY, CARDIOTHORACIC CENTRE  
ALL INDIA INSTITUTE OF MEDICAL SCIENCES, NEW DELHI-110029

NAME: Satyam Kumar AGE: 7y 5m SEX: MF DATE: 29/4/2024  
ECHO NO.: ..... CV NO.: ..... UHID NO.: 109104855 C.R. No.: .....  
HEIGHT: .....cm WEIGHT: .....Kg. BSA: .....m<sup>2</sup> ref. Physician: P.K

Referring Diagnosis: .....  
Quality of Imaging: Poor/Adequate/Good Done by Dr. Abhishek Checked by Dr. ....

**MITRAL VALVE**  
Morphology: Normal/Thickening/Calcification/Flutter/Vegetation/Prolapse/SAM/Doming  
PML Normal/Thickening/Calcification/Prolapse/Paradoxical motion/Fixed.  
Doppler: Subvalvular deformity present/Absent Score: .....  
Normal/Abnormal  
Mitral stenosis Present/Absent RR Interval: .....msec  
EDG: .....mmHg MDG: .....mmHg MVA: .....cm<sup>2</sup>  
Mitral regurgitation Absent/Trivial/Mild/Moderate/Severe

**TRICUSPID VALVE**  
Morphology: Normal/Atresia/Thickening/Calcification/Prolaps/Vegetation/Doming  
Doppler: Normal/Abnormal  
Tricuspid stenosis Present/Absent RR Interval: .....msec  
EDG: .....mmHg MDG: .....mmHg  
Tricuspid regurgitation Absent/Trivial/Mild/Moderate/Severe Fragmented Signals

**PULMONARY VALVE**  
Morphology: Normal/Atresia/Thickening/Doming/Vegetation  
Doppler: Normal/Abnormal  
Pulmonary stenosis Present/Absent Level  
Pulmonary Regurgitation PSG .....mmHg Pulmonary annulus: .....mm  
Early diagnostic gradient: .....mmHg Present/Absent  
End Diastolic gradient: .....mmHg

**AORTIC VALVE**  
Morphology: Normal/Thickening/Calcification/Restricted opening/Flutter/Vegetation No. of cusps: 1/2/3/4  
Doppler: Normal/Abnormal  
Aortic stenosis Present/Absent Level  
Aortic regurgitation PSG .....mmHg Aortic annulus: .....mm  
Absent/Trivial/Mild/Moderate/Severe

Child Life Care Foundation

D-101, बुद्ध विहार कामर्शियल, तारामण्डल, पैडलगाज थ रुस्तामपुर हाइव पर 1111333  
Mobile: 7668006926 96059000070  
(य.पी)

for clo

हृदय वक्ष एवं तंत्रिका विज्ञान केन्द्र  
 ब० रो० वि०  
 अ० भा० आ० सं०, नई दिल्ली-110029  
 Cardiothoracic & Neurosciences Centre, O.P.D.  
 A.I.I.M.S., New Delhi-110029

दिनांक/Date

विभाग  
 Deptt.

यू०एच०आई०डी०सं०  
 UHID No.

CV 2026/014/0013540      २०      Cardiology  
 UHID: 109104855      Paed.Cardiology  
 Date 27/04/2026      MON      7Y 5M /M  
 Name SATYAM KUMAR  
 S/O CHANCHAL PRASAD      General  
 Phone No. 7880548624      Dr. S  
 Consultant Room 21      RAMAKRISHNAN  
 SR Room 14      DR ABHISHEK  
 Prv. Reg. No.

Diagnosis

27/4/26      ACHD / TQ, / Large pm vsd / mod. A2

ADW

- 1) Tab lasix 10mg po BD
- 2) Tab Aldactone 25mg 1/2 - 1/2
- 3) Sy vit cotol 5ml po OP  
 (5ml / 32-97)
- 4) R/w rep 48 in OPD

*[Handwritten signature]*

27  
 4:30  
 SpO2 - 100%  
 HR - 85  
 ECG  
 - NSR  
 - HR - 96/M  
 - NAD  
 - LVH/LVVO f



V 2026/014/0013540  
 HID: 109104855  
 Date 27/04/2026  
 Name **SATYAM KUMAR**  
 DO CHANCHAL PRASAD  
 Phone No. 7880548624  
 Consultant Room 21  
 R Room 14

₹0  
**Cardiology**  
**Paed. Cardiology**  
 7Y 5M / M  
 General  
 Dr. S  
**RAMAKRISHNAN**  
 DR ABHISHEK  
 Prv. Reg. No.

Centre  
 L-26594866  
 129  
 orm

24A

Date.....  
 27/04/26

Paste  
 Patients Details:  
 UHID:

S.NO.	(Tick the entire panel or encircle the required tests in the panel)
1	<input checked="" type="checkbox"/> CBC / ESR
2	<input checked="" type="checkbox"/> LFT (Total Bilirubin / Direct / Indirect / SGOT (AST) / SGPT (ALT) / Alkaline Phosphates (ALP) / Albumin / Globulin / Total Protein / Albumin - Globulin ratio)
3	<input checked="" type="checkbox"/> KFT (Urea / Creatinine / Sodium / Potassium / Uric Acid / Chloride)
4	<input checked="" type="checkbox"/> LIPID PROFILE (Total Cholesterol / LDL - Cholesterol / HDL - Cholesterol / VLDL Cholesterol / Triglycerides / LDL - HDL Ratio)
5	<input checked="" type="checkbox"/> THYROID FUNCTION TEST (T3 / T4 / TSH / FT3 / FT4)
6	<input type="checkbox"/> HbA1c
7	<input type="checkbox"/> Glucose Fasting / APP
8	<input type="checkbox"/> CRP
9	<input type="checkbox"/> ASO
10	<input type="checkbox"/> Viral Markers
11	<input type="checkbox"/> HORMONES (Cortisol / Estradiol / FSH / LH / Intact PTH / Progesterone / Prolactin / Testosterone)
12	<input type="checkbox"/> VITAMINS (Vitamin D3 / Vitamin B12 / Serum folate)
13	<input type="checkbox"/> DRUGS (Carbamazepine / Valproic acid / digoxin, cyclosporine, tacrolimus / everolimus / Phenytoin (Eptoin))
14	<input type="checkbox"/> IRON STUDY PANEL (Iron / TIBC / Transferrin / Ferritin / % Saturation)
15	<input type="checkbox"/> Prothrombin Time / INR / APTT
16	<input type="checkbox"/> Coagulation Factors (D-Dimer / ATIII, Protein C, Protein S, Factor V Leiden)
17	<input type="checkbox"/> Homocysteine
18	<input type="checkbox"/> Cardiac Markers (NT proBNP / CK / CK-MB / Troponin T / Myoglobin)
19	<input type="checkbox"/> Catecholamines : Plasma / 24-hour Urine
20	<input type="checkbox"/> MISCELLANEOUS TEST: Fibrinogen / Total PSA / RA Factor / AFP / NMOSD / MOG / Procalcitonin / Total Amylase / Autoimmune Encephalitis Panel
21	<input type="checkbox"/> Any other test (Please mention the name) :

Child Life Care Foundation

*[Handwritten signature]*

Consultant Signature.....

हृदय वक्ष एवं तंत्रिका विज्ञान केन्द्र  
CARDIO-THORACIC & NEURO-SCIENCES CENTRE

(42)

अखिल भारतीय आयुर्विज्ञान संस्थान

A. I. I. M. S. Hos

नाम

Name

एक्स-रे नम्बर

X-Ray No.

हस्पताल यू.एच.आई.डी.  
Hosp. UHID No.

एक्सरे जांच के लिए अ

Examination Required

चिकित्सक की जांच रिपोर्ट :

Clinical Information :

CV 2026/Ina/0013540

UHID: 109104855

Date 27/04/2026

Name SATYAM KUMAR

S/O CHANCHAL PRASAD

Phone No. 7880548624

Consultant Room 21

SR Room 14

MON

Cardiology  
Paed. Cardiology

TY SM/AM

General

Dr. S

RAMAKRISHNAN

DR ABHISHEK

Prv. Reg. No.

एक्सरे-फार्म

REQUISITION FORM

लिंग

आय

Sex

Income

विभाग

g Unit

ते

Ambulatory/Non

CXR - PA

Child Life Care Foundation

किसी दवा का बुरा प्रभाव

Any History of Allergy

अन्तिम माहवारी तिथि

LMP

कोई पुराने एक्स-रे

Any Previous X-Rays

चिकित्सक के हस्ताक्षर

SIGNATURE OF MEDICAL OFFICER

रेडियोग्राफर के लिए

FOR RADIOGRAPHERS USE

पहचान चिन्ह

Identification Mark

अंगूठा निशान

Thumb Impression

कमरा नं. Room No.	फिल्म साइज Size & No. of Films	के. वी. KV	एम.ए.एस. MAS
हस्ताक्षर / Signature			

रिपोर्ट

REPORT

एक्स रे-चिकित्सक

RADIOLOGIST

Left aortic arch with normal branching pattern, No CoA / PDA.  
Normal systemic & pulmonary venous connection, No LSVC.  
Good biventricular contractility.

**Final Diagnosis:**

Originally Large PM - VSD(11.7x9mm on LV side) with outlet extension (effective size -5mm) significantly restricted by RCC, NCC commissural prolapse with significant RCC buckling with Lt. to Rt. shunt with gdt of 48mmHg  
RV cavity muscle bundle with gdt of 21mmHg.  
Dilated LA/LV, Moderate AR with eccentric jet, AR VC - 0.34

**Child Heart Care Team Decision:**

Family counselled about Very complex CHD & Delayed presentation.  
Needs early VSD closure + Ao valve Repair/Replacement + DCRV Repair.  
Refer to surgical team.


**Note:**

CXR:- CTr - 0.5, LV apex. Increased PBF.

**Prescription Notes:**

Tab. Lasix(40mg) 10mg BD

Tab. Spironolactone(25mg) 12.5mg BD

  
Dr. Yogesh C Sathe  
Pediatric Cardiologist

**Child Life Care Foundation**

Dr. Prashant Thakur  
Pediatric Cardiologist

Dr. Deendayal Nagar  
Pediatric Cardiologist

→ Cardiology ETC का सिर्द  
↓  
CTNS

All Medical Services viz, OPD, Investigations, Admission, Surgeries, Interventions, including food are provided TOTALLY FREE OF COST. There are no charges / fee of any kind levied on the patients at



# PACE

## HEART CENTRE PVT. LTD.

D-101, Budh Vihar Commercial, Taramandal,  
 Paidaleyganj to Rustampur Highway, Gorakhpur (U.P.)  
 Mobile : 7668006926, 9695889878  
 Timing : 10.00 am to 6.00 pm  
 Sunday Closed

PATIENT ECHO WINDOW :- POOR / ADEQUATE / GOOD

**M-MODE MEASUREMENTS :-**

AORTA:.....36.....mm; LEFT ATRIUM:.....35.....mm  
 RVIDd :.....mm  
 IVSd : .....7.....mm ; IVSs :.....11.mm  
 LVIDd : .....64.....mm ; LVIDs:.....45.....mm  
 LVPWd : ...7.....mm ; LVPWs:..12.....mm  
 EPSS : .....mm  
 LV MASS :.....  
 IVS/LVPW RATIO :.....  
 FS :.....25.0.% ; LVEF :.....52.0.%  
 EDV : ..... ; ESV : .....  
 IVS: NORMAL / SIGMOID / PARADOXICAL  
 IVS: VSD  
 IAS : INTACT

**CARDIAC CHAMBERS :-**

LEFT VENTRICLE :- Normal / Hypertrophy / Dilated / Thinned out / Aneurysmal  
 FUNCTION :- Normal / Reduced  
 RIGHT VENTRICLE :- Normal/Hypertrophy/Dilated/Apical Obliteration/Rudimentary  
 FUNCTION :- Normal / Reduced  
 LEFT ATRIUM :- Normal / Enlarged  
 RIGHT ATRIUM :- Normal / Enlarged  
 PERICARDIUM :- Normal / Absent / Thickened / Calcified / Constriction / Mass / Effusion  
 IV. VOLUME & EF :-

Child Life Care Foundation

**M-MODE :-**

ESV : .....ml/m2  
 EDV : .....ml/m2  
 EF : ....55.0.%

**MOD. SIMPSON :-**

ESV : .....ml/m2  
 EDV : .....ml/m2  
 EF : .....%

**MITRAL VALVE STUDY :-**

ANTERIOR MITRAL LEAFLET :- Normal/Thickened/Doming/Calcified/Prolapse  
 /Flail/SAM/Cleft/Perforation/Restricted Mobility

POSTERIOR MITRAL LEAFLET :- Normal/Thickened/Doming/Calcified/Prolapse  
 /Flail/SAM/Flat/Fixed/Cleft/Perforation/Restricted Mobility/Paradoxical

MITRAL VALVE SCORE :- Thickness :-  
 Subvalvular.Apparatus :-  
 Total :-

Mobility :-  
 Calcification :-

MITRAL STENOSIS :- Absent / Mild / Moderate / Severe

MVA:.....cm2; .....cm2  
 (By 2D), (By PHT)

Max. Gradient :.....mm Hg ;MDG :.....mm Hg ;HR :...../min.

**AVAILABLE**

- graph
- graphy and Colour Doppler
- ardiography
- ageal Echocardiography
- ◆ Temporary Pacemaker
- ◆ Permanent Pacemaker
- ◆ Coronary Care Unit
- ◆ Private Room
- ◆ Angiography
- ◆ Angioplasty

हृदय वक्ष एवं तंत्रिका विज्ञान केन्द्र  
**CARDIOTHORACIC & NEUROSCIENCES CENTRE**  
 अखिल भारतीय आयुर्विज्ञान संस्थान, नई दिल्ली-११००२६  
 A.I.I.M.S., New Delhi-110026

62

विशेष जांच पड़त  
 Requisition for

दिनांक  
 Date

नाम  
 Name

क्लिनिक डायगनासि  
 Clinical Diagnosis:

दवाईयाँ  
 Drugs

जांच पड़ताल की माँग  
 Investigations requested

इको  
 ST/Echo / Vector / Redionucleiude Study / Others

CV 2026/014/0013540

UHID: 109104855

Date 27/04/2026 MON

Name SATYAM KUMAR

S/O CHANCHAL PRASAD

Consultant 21

Address: THAVAI TALA KASHI NAGAR, UTTAR PRADESH INDIA

Cardiology  
 Paed. Cardiology

7Y 5M /M

C  
 UI  
 D:  
 N  
 S/श  
 Card

बिस्तर  
 Bed

Child Life Care Foundation

विचारार्थ  
 Ref. by

ECHO on wednesday @ 2PM -

@ 2PM -

29/4/26

1090 AM VSD (L-R)

DILAYAL LA

हस्ताक्षर परामर्शदाता  
 Signature of Consultant



# PACE

## HEART CENTRE PVT. LTD.

D-101, Budh Vihar Commercial, Taramandal,  
Paidaleyganj to Rustampur Highway, Gorakhpur (U.P.)  
Mobile : 7668006926, 9695889878  
Timing : 10.00 am to 6.00 pm  
Sunday Closed

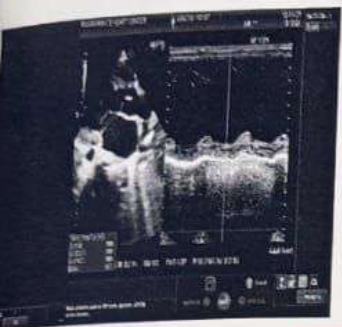
Name :: MASTER SATYAM

Sex/Age :: Male/8 Years

Patient ID :: 16Mar2026\_024

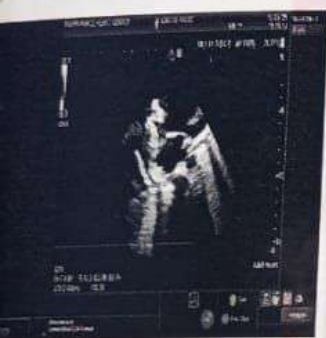Procedure ::  
ECHOCARDIOGRAPHY

Date :: Mar 16, 2026



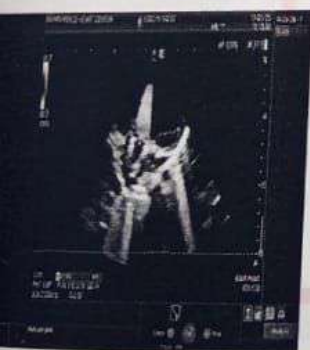### SPECIAL COMMENT :-

- NO CLOT/VEGETATION/PERICARDIAL EFUSSION/RWMA.
- SITUS SOLITUS. BASE TO APEX LEFT.
- AV & VA CONCORDANT.
- IVC TO RA & 3PV TO LA.
- GREAT ARTERIAL RELATIONS NORMAL.
- NO ASD/ PDA/ CoA.
- MODERATE SIZE [7.0mm] SUB - AORTIC VSD WITH LEFT TO RIGHT SHUNT >2:1.

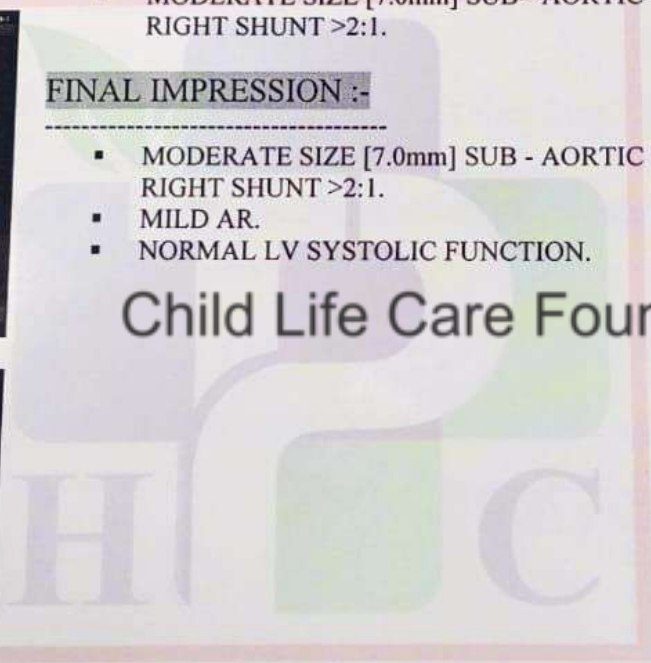


### FINAL IMPRESSION :-

- MODERATE SIZE [7.0mm] SUB - AORTIC VSD WITH LEFT TO RIGHT SHUNT >2:1.
- MILD AR.
- NORMAL LV SYSTOLIC FUNCTION.



## Child Life Care Foundation




S AVAILABLE

ography  
est  
ography and

DR. ATUL KR. SHAHI M.D. D.M.

- ◆ Temporary Pacemaker
- ◆ Permanent Pacemaker
- ◆ Private Room
- ◆ Angiography





NEHRU HOSPITAL BRD MEDICAL COLLEGE  
GORAKHPUR  
UTTAR PRADESH



ABHA Address : 91202845417858@abdm/ Abha No : 91-2028-4541-7858

पंजीकरण संख्या (Registration No (UHID)) : 20260108067

टोकन संख्या (Token No) : 31

कमरा संख्या (Room No) : SEPARATE BUILDING, 500 BEDS HOSPITAL, Ground, Room - 16

Doctor Days : MONDAY

Pediatrics OPD

नाम (Name) : Mr. Satyam Kumar

उम्र/ लिंग (Age/Sex) : 6Y / M

विभाग (Department) : Paediatrics

विभाग पंजीकरण संख्या (Dept. Reg. No) : 20260007731

डॉक्टर : Dr Bhoopendra Sharma Dr Vikas Agrawal Dr Ameen

रोगी का प्रकार (Patient Type) : General

रक्षक का नाम (Guardian Name) :

पंजीकरण राशि (Registration Amount) : Rs. 1

मोबाइल नंबर (Mobile No) : \*\*\*\*\*445

पता (Address) : RO THAWI TOLA PS PATHERWA, KUSHI NAGAR (UTTAR PRADESH)

पंजीकरण की तिथि (Date of Registration) : 06/04/2026 12.36 PM

ओ पी डी नं-16  
बाल रोग विभाग

यूनिट-A-सोमवार

MLC Patient : NO

वजन - 15.6 Kg  
- 11719

Review in Pediatric - OPD

Δ - VSD ?

Refer to CARDIOLOGY

Child Life Care Foundation

Referred to Higher centre for further workup and management  
(Plimbo Lkw, SHPGI Lkw)  
(Rm Lkw, Pediatric Cardiology)

HR - 102/min  
EPR - 94%  
RR - 24/min  
BP - 104/64 mmHg

Adv 2D Echo

Moderate size (7.0mm) SUB-AORTIC VSD  
↳ Left to Right shunt > 2:1  
mild AR  
Normal LV systolic function

यह पर्चा 15 दिनों के लिए मान्य है।

Dr. Mr. Ashutosh Kumar Singh

Date Time: 06/04/2026 12.36 PM



डा. अतुल कुमार शाही

**DR. ATUL KUMAR SHAHI**

M.D. (Medicine), D.M. (Cardiology)

P.G.I. Chandigarh

हृदय रोग विशेषज्ञ

Reg. No. 33939 (MCI-UP)



**पेय**

**हार्ट सेन्टर प्रा. लि.**

**D-101, बुद्ध विहार कामर्शियल, तारामण्डल, पैडलेगंज से रुस्तमपुर हाईवे पर, गोरखपुर. मोबाईल : 7668006926, 9695889878**

Pt's Name : Mr. Satyam Kumar Residence : Bandila Age/Sex : 42 m Date : **16 MAR 2026**

Condition : Tamponade ECG : Normal PR : BP : JVP :

Mild AR EF : 70 Pall / cya / clubbing / Ped. Oed. / Jaundice

CART : CVS : Respiratory :

PCI : ABD : CNS :

TEMP :

Ad. Smg.

Ti Amifm 40/2000

Amifm MD  
Cardiology

By a limit

**Child Life Care Foundation**



Child Life Care Foundation